

January-June 2021

Volume 30

Issue 1

PRINT ISSN: 2277-1867

ONLINE ISSN: 2277-8853



# JOURNAL OF FORENSIC MEDICINE SCIENCE AND LAW

Official Publication of Medicolegal Association of Maharashtra

**Editor-in-chief**

Dr Ravindra Deokar

**Associate Editors**

Dr Sadanand Bhise

Dr Sachin Patil

**MULTISPECIALITY, MULTIDISCIPLINARY, NATIONAL  
PEER REVIEWED, OPEN ACCESS, MLAM (SOCIETY) JOURNAL**

**Editorial Office Address**

Department of Forensic Medicine & Toxicology, Third Floor, Library Building, Seth G S Medical College & KEM Hospital, Parel, Mumbai, Maharashtra, India. Pin-400 012. Email id: [mlameditor@gmail.com](mailto:mlameditor@gmail.com) Phone: 022-24107620 Mobile No. +91-9423016325.



# JOURNAL OF FORENSIC MEDICINE SCIENCE AND LAW

(Official Publication of Medicolegal Association of Maharashtra)  
Email.id: [mlameditor@gmail.com](mailto:mlameditor@gmail.com)

PRINT ISSN:  
2277-1867

ONLINE ISSN:  
2277-8853

## Case Report

### Sudden Unexpected Death Due to Acute Hemorrhagic Pancreatitis

Daideepya C Bhargava<sup>a</sup>, Atul S Keche<sup>b</sup>, Brinda Patel<sup>c</sup>, Ashwini Tandon<sup>d</sup>, Vivek K Chouksey<sup>c</sup>

<sup>a</sup>Junior Resident, <sup>b</sup>Associate Professor, <sup>c</sup>Senior Resident, <sup>d</sup>Additional Professor

Department of Forensic Medicine and Toxicology, AIIMS, Bhopal, Madhya Pradesh, India. Pin- 462020.

#### Article Info

**Received on:** 30.01.2021

**Accepted on:** 21.02.2021

#### Key words

Sudden death,  
Hemorrhagic  
necrotizing pancreatitis,  
Coagulative necrosis,  
Fatty liver.

#### Abstract

Sudden and unexpected death is an important indication for medico-legal autopsy. It is done for establishing the cause of death in such suspicious cases. It is a challenge for a forensic expert to determine a cause of death in sudden and unexpected death cases. Sudden death involving the pancreatic abnormalities remains a rare and unusual condition. The rapid progressing disease condition is one of the reason behind the sudden unexpected death due to pancreatitis. While a large number of studies have dealt with the clinical picture, course, and outcome of acute pancreatitis in the clinical setting, postmortem studies of fatal acute pancreatitis, and particularly those dealing with medicolegal autopsy cases, are sparse. We report a case of a 45-year-old man without a significant past history who suddenly died at his home. Gross autopsy findings and histopathological examination findings lead to the specific diagnosis. Gross examination during autopsy revealed severe pathology in and around pancreas which was pointing to a particular cause of death. Histopathology of the pancreas revealed acute inflammation and coagulative fatty necrosis. This paper highlights a case of acute hemorrhagic pancreatitis which is not so common in current forensic practice, thus it is being reported.

#### 1. Introduction

Sudden deaths are mostly natural deaths, which occur immediately or within 24 hours of the onset of terminal symptoms.<sup>1,2</sup> Most of the sudden deaths are mainly attributed to the cardiovascular system to the extent of 45%, 25% are related to the respiratory system, 20% to the nervous system and 10% are due to other causes.<sup>3</sup> Sudden pancreatic death remains a rare and unusual condition although acute pancreatitis is a common surgical emergency. Incidence of acute pancreatitis cases in urban population is increasing nowadays, probably due to increase in alcohol abuse. Alcoholism ranks the first

among the etiological factors of acute pancreatitis.<sup>4</sup> The autolyzed tissue in pancreas is often hemorrhagic and may be mistaken for acute pancreatitis, though Histopathological examination rapidly resolves the problem.<sup>5</sup> Autopsy findings when supported by histopathology immensely help in determining cause of death especially in cases of sudden deaths including those related with pancreatic pathology. Sometimes severe acute pancreatitis can be complicated by multiorgan failure which can be fatal in more than 50% of cases. But sudden pancreatic death remains an unusual condition.<sup>6</sup>

**How to cite this article:** Bhargava DC, Keche AS, Patel B, Tandon A, Chouksey VK. Sudden Unexpected Death Due to Acute Hemorrhagic Pancreatitis. J For Med Sci Law 2021;30(1):61-65.

\*Corresponding author: Dr Atul Keche, Associate Professor, Department of Forensic Medicine and Toxicology, AIIMS, Bhopal, Madhya Pradesh, India. Pin- 462020. E mail- [atul.fmt@aiimsbhopal.edu.in](mailto:atul.fmt@aiimsbhopal.edu.in) (M): +91-8208072886.

Acute pancreatitis represents a spectrum of disease, characterized by 'inflammation of the pancreas ranging from a mild, transitory illness to a severe, rapidly progressive hemorrhagic form, with massive necrosis and mortality rates of up to 24%. Its causal relationship with sudden death should always be kept in mind.<sup>7</sup> Patients with pre-existing diabetes mellitus have a 94% increased risk of suffering from acute pancreatitis. It is still unknown if acute pancreatitis is the cause of uncontrolled diabetes or diabetic ketoacidosis leads to acute pancreatitis.<sup>8</sup>

## 2. Case Report:

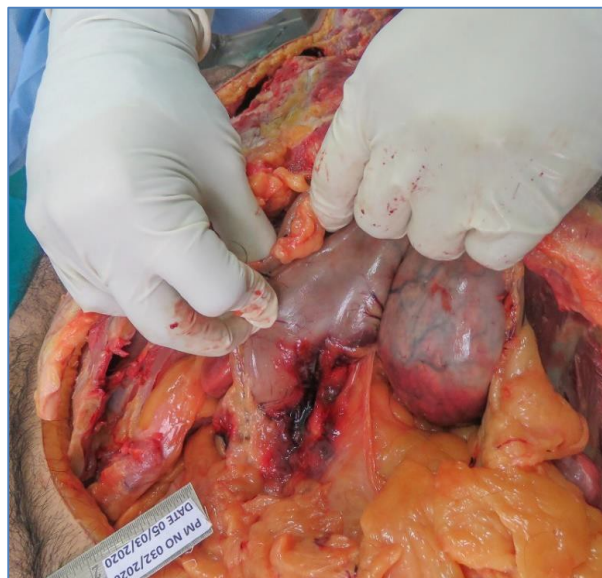In the month of March, a 45-year-old businessman, apparently healthy, who was living with his mother in a duplex, was found dead in his bed room upstairs at around 11:00 a.m. by his mother when he didn't show up for his regular morning tea. Immediately he was brought to AIIMS emergency where he was declared brought dead. Then body was sent to mortuary for Postmortem examination. Past history was not significant.

**On external examination-** It was an average built and moderately nourished body. Eyes were closed, cornea clear and pupils were dilated. Mouth was closed and dried blood was seen trickling down from angle of mouth towards the ear lobule on both the sides. Tongue was inside the mouth cavity and teeth were intact. Rigor mortis was well developed all over the body. Postmortem lividity was present on back and was fixed. There were no signs of decomposition.

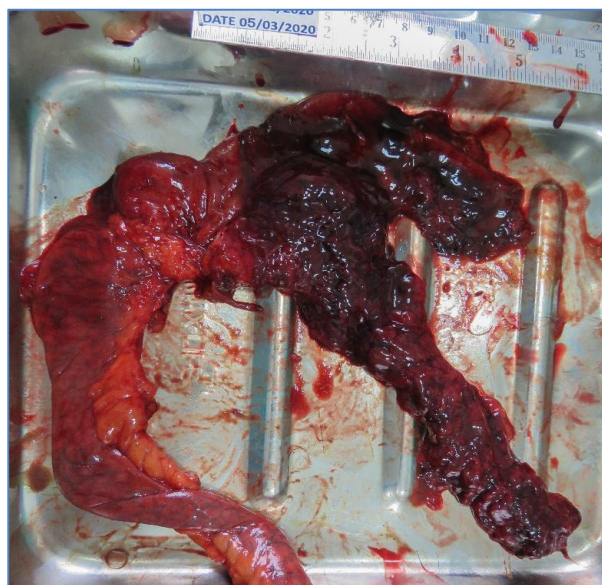
**On internal examination:** Mild retroperitoneal hemorrhage was evident (**Figure-1**) and after evisceration of pancreatic tissue block the gross appearance was suggestive of acute hemorrhagic pancreatitis (**Figure-2**) and histological findings revealed the severe pancreatic pathology (**Figure-3, 4 & 5**). Histological examination of the pancreas showed neutrophilic infiltration and many optically empty areas, compatible with necrosis of fat and adipose tissue due to acute hemorrhagic pancreatitis. Liver was enlarged (Weight-2025 gm) (**Figure-6**). Histopathology of liver showed marked fatty changes (**Figure-7,8**) Intrahepatic cholestasis and portal triaditis was evident with mild periportal inflammation (**Figure-9**). Severe congestion was observed in the brain, lungs, kidneys and liver. In heart, left coronary artery showed about 80% block in its lumen. We concluded that the cause of death is due to combined effect of pathology in pancreas and Left coronary artery occlusion (80%). In the present case, there was no significant past history.

Meticulous autopsy evaluation and histopathological examination, was useful in determining the cause of death.

**Figure 1:** In situ view of acute hemorrhagic pancreatitis with retroperitoneal hemorrhage.



**Figure 2:** Gross appearance of acute hemorrhagic pancreatitis after evisceration of tissue block.

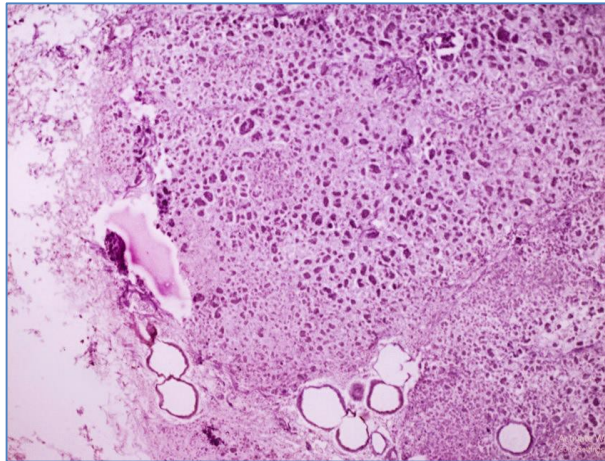


## 3. Discussion:

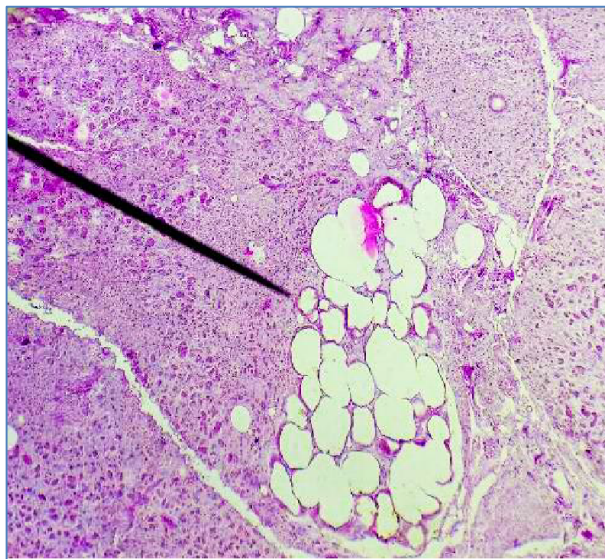Acute pancreatitis was found in about 4.9% of patients who visited the hospital with a complaint of acute abdominal pain.<sup>3</sup> Acute pancreatitis is quite difficult to diagnose and it is often missed clinically.<sup>9</sup> Severe acute pancreatitis or hemorrhagic pancreatitis is associated with mortality rates ranging from 10-30%. Some authors report that acute pancreatitis without hemorrhage may also

cause death, but hemorrhagic pancreatitis is more commonly reported in autopsies related to sudden deaths.<sup>10</sup>

**Figure 3:** (H & E, 20x): Pancreas showing marked coagulative necrosis with ghost outline of cells and fat necrosis at periphery.



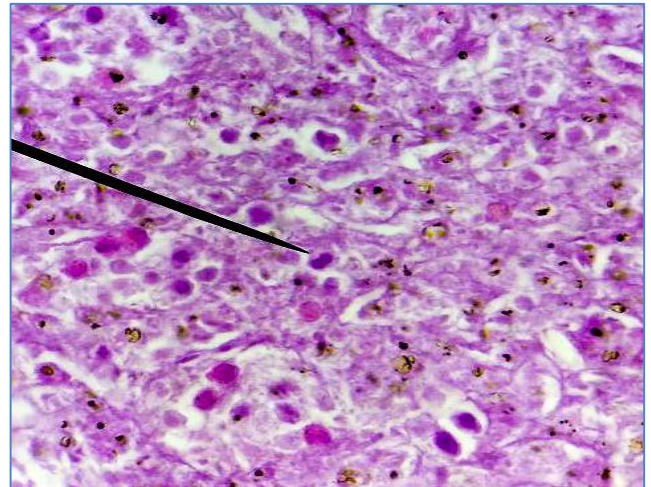
**Figure 4:** (H & E, 4x). Section of pancreas showing Necrotic foci.



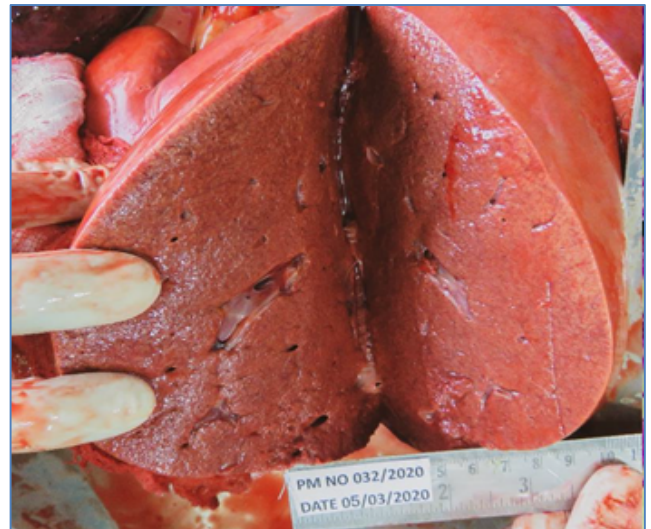M Tsokos et al. reported that the overall mortality rate of acute edematous pancreatitis is below 1%, but when considering the severe hemorrhagic form of the disease, mortality rates range from 13.5%–24%.<sup>9</sup> In sudden deaths, determining the cause of death is a tough job for forensic experts. Acute hemorrhagic pancreatitis is one of the conditions where careful postmortem examination is required to opine the cause of death. Here we are reporting a case of sudden death due to pancreatic etiology which was revealed only after autopsy. Among the additional associated autopsy findings, fatty liver was present in 41%, liver cirrhosis

in 26%, heart pathology in 33% and in 26% cases chronic bronchitis was found.

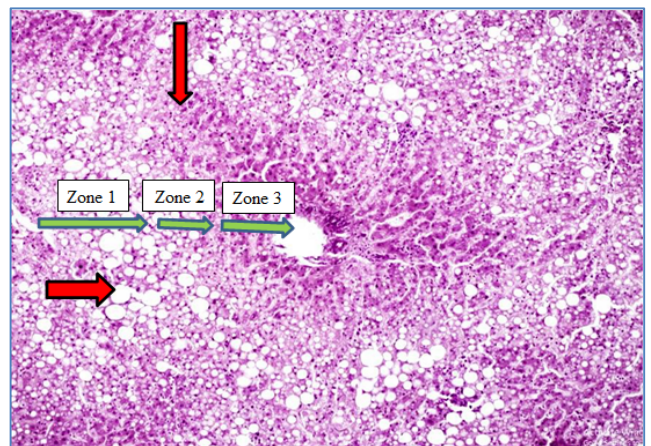
**Figure 5:** (H & E, 100x). Neutrophilic infiltration in pancreatic tissue suggestive of Acute inflammation.



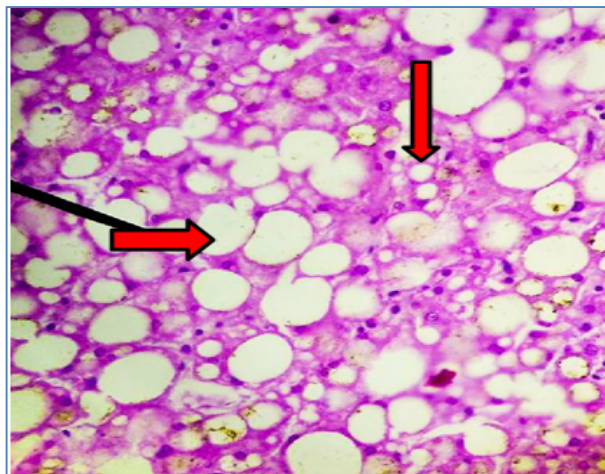
**Figure 6:** Gross appearance of enlarged liver.



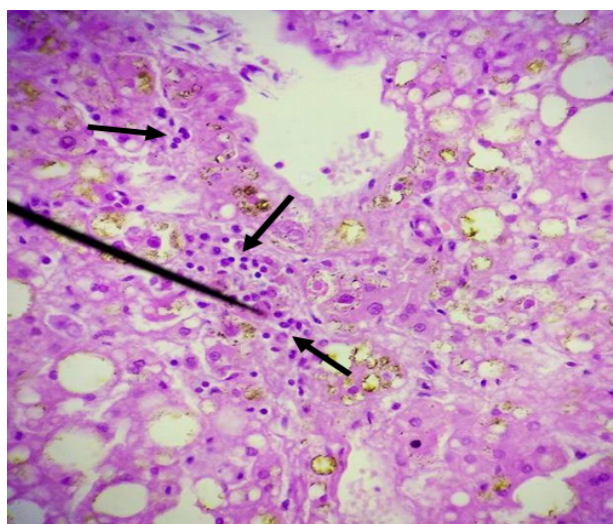
**Figure 7:** (H & E, 20x). Fatty liver with steatosis (micro vesicular and macro vesicular) in zone 1 of liver.



**Figure 8:** (H & E, 40x). Histopathological examination of the Liver tissue block reveals macro as well as micro vesicular steatosis.



**Figure 9:** (H & E, 40x). Neutrophilic infiltration in liver tissue suggestive of steatohepatitis.



The mean age of male subjects was 47 years and that of female was 60 years and the mean age for all subjects together was 52 years. Shetty et al in their case series concluded that the mean age of their series was 35 years. Although no seasonal variations, 63% fatalities occurred during October-April. History of chronic alcohol consumption could be established in 70% of cases. It has been reported that, about 74% people who are socially isolated and not having any contact to family or neighbors, or homeless people commonly suffer from this disease.<sup>3,9</sup> In type 2 diabetes there is 84% increased risk of suffering from acute pancreatitis.<sup>8</sup>

Interstitial edema and an inflammatory infiltrate were found in mild cases of acute pancreatitis, usually with no organ dysfunction.

Pancreatic parenchyma showed extensive inflammation and necrosis, often associated with severe gland dysfunction and multiorgan failure in severe cases. This study by Shetty et al also showed hemorrhage in the peritoneal cavity in all the cases.<sup>3</sup> Hemorrhagic pancreatitis is more commonly associated with frank intra-peritoneal hemorrhage. Microscopic evidence of acute inflammation is confirmatory finding for the diagnosis of acute pancreatitis as the gross finding of it may be mistaken for those of postmortem autolysis.<sup>10</sup> In the routine autopsy, the frequent diagnostic difficulty faced by the autopsy surgeon is this autolysis of the pancreatic specimens due to its enormous enzymatic activity. Loss of architecture due to post mortem autolysis leads to the loss of significant findings. Hence the better time interval for studying pancreas histologically is till 8 hours after death.<sup>3</sup>

This case highlights the role forensic expert in determining the cause of sudden death. In such a situation, history, circumstances of death, meticulous autopsy and histopathology are needed to find out the exact cause of death.

#### 4. Conclusion:

Missed clinical diagnosis of acute pancreatitis is a well-known problem. Forensic experts are likely to encounter pancreatitis at autopsy examination and thus must be familiar with the gross and histopathological findings. Serum amylase levels, ultrasonography and computed tomography are recommended for early diagnosis of this condition.

**Funding:** None.

**Competing interests:** None.

#### References:

1. Shetty CK, Shetty SS. Acute Haemorrhagic Pancreatitis Leading to Sudden Unexpected Death - A Case Report and Review of Literature. In 2015.
2. Raj K, Chaudhari VA, Gochchait D, Devan M. Sudden death due to acute hemorrhagic necrotizing pancreatitis. *J Indian Acad Forensic Med.* 2019;41(3):216-8.
3. Shetty BS, Bloor A, Menezes RG, Shetty M, Menon A, Nagesh KR, Pai MR, Mathai AM, Rastogi P, Kanchan T, Naik R. Postmortem diagnosis of acute haemorrhagic pancreatitis. *Journal of forensic and legal medicine.* 2010 Aug 1;17(6):316-20.
4. An Epidemiological Study of Acute Pancreatitis in Rural Population [Internet]. Available from: [http://jms.ac.in/index.php?option=com\\_k2&view=](http://jms.ac.in/index.php?option=com_k2&view=)

item&id=60:an-epidemiological-study-of-acute-pancreatitis-in-rural-population&Itemid=76.  
[Assessed on 5<sup>th</sup> Jun 2020]

5. Saukko P, Knight B. Knight's Forensic Pathology. 4 edition. Boca Raton: CRC Press; 2015. 680 p.
6. Sahnoun M, Meksi Y, Jedidi M, Yaa-coubi T, Majdoub A. Acute lethal pancreatitis forensic diagnosis. *Pancreas Open J.* 2017;2(1):1-3.
7. Rastogi P, Palimar V. Sudden death due to acute haemorrhagic pancreatitis. *Journal of Indian Academy of Forensic Medicine.* 2009;31(4):377-8.
8. Jin C, Jin L. Sudden Death in a Patient with Undiagnosed Diabetes, Acute Pancreatitis and Acute Adrenalitis. *Forensic Medicine and Anatomy Research.* 2019 Aug 14;7(04):63.
9. Tsokos M, Braun C. Acute pancreatitis presenting as sudden, unexpected death: an autopsy-based study of 27 cases. *The American journal of forensic medicine and pathology.* 2007 Sep 1;28(3):267-70.
10. Stoppacher R. Sudden death due to acute pancreatitis. *Academic forensic pathology.* 2018 Jun;8(2):239-55.