

July - December 2021

Volume 30

Issue 2

PRINT ISSN: 2277-1867

ONLINE ISSN: 2277-8853



# JOURNAL OF FORENSIC MEDICINE SCIENCE AND LAW

Official Publication of Medicolegal Association of Maharashtra

**Editor-in-chief**

Dr Ravindra Deokar

**Associate Editors**

Dr Sadanand Bhise

Dr Sachin Patil

**MULTISPECIALITY, MULTIDISCIPLINARY, NATIONAL  
PEER REVIEWED, OPEN ACCESS, MLAM (SOCIETY) JOURNAL  
Indexed with Scopus (Elsevier) & Index Copernicus (Poland)**

**Editorial Office Address**

Department of Forensic Medicine & Toxicology, Third Floor, Library Building, Seth G S Medical College & KEM Hospital, Parel, Mumbai, Maharashtra, India. Pin-400 012. Email id: [mlameditor@gmail.com](mailto:mlameditor@gmail.com) Phone: 022-24107620 Mobile No. +91-9423016325.



# JOURNAL OF FORENSIC MEDICINE SCIENCE AND LAW

(Official Publication of Medicolegal Association of Maharashtra)  
Email.id: [mlameditor@gmail.com](mailto:mlameditor@gmail.com)

PRINT ISSN:  
2277-1867

ONLINE ISSN:  
2277-8853

## *Original Research Article*

### **Age Estimation from Morphological Changes in Sternal End of Fifth Rib**

Rohit Bharti<sup>a</sup>, Anshul Saxena<sup>a\*</sup>

<sup>a</sup>Assistant Professor, Department of Forensic Medicine and Toxicology, School of Medical Sciences and Research, Sharda University, Greater Noida, UP, India. Pin-201306.

#### Article Info

**Received on:** 11.03.2021

**Accepted on:** 01.12.2021

#### Key words

Age estimation,  
Sternal end,  
Phase Technique,  
Forensic Anthropology.

#### Abstract

**Background:** Medico-legal proceedings are highly dependent on the age estimation of an individual, and a method for age determination for one population cannot be applied to another population. There is a need for a sensitive India-specific instrument to determine age of an individual. **Material & Methods:** In this study, phase analysis method has been used to study the morphological changes in the sternal end of the fifth rib and to further assist in age estimation. A cross-sectional descriptive study was carried out in Maulana Azad Medical College, New Delhi. 150 cases brought to the Department of Forensic Medicine for post-mortem were recruited. The sternal ends of the fifth rib from both sides were isolated and studied, and age of the individual was estimated based on three components. The morphological changes in the sternal ends were found to be in accordance with the age of an individual. There was no difference in the findings of bilateral sides on all components. **Conclusion:** The results of this study reveal that morphological changes in the sternal ends of the fourth ribs gave an encouraging result for estimation of age by component method also.

#### 1. Introduction

The determination of age at death is an important part of physical and forensic anthropology.<sup>1</sup> Medico-legal proceedings make it an imperative to accurately estimate the age of an individual as many laws and criminal codes are dependent on the age of the victim or the accused. Numerous parts of the human body can be used to assist in estimation of age such as ribs, clavicle, thyroid cartilage, scapula, vertebral column, sternum, pelvis etc. Finding skeletal remains is of frequent occurrence in forensic practice but smaller bones are found to be relatively intact, compared to long bones

in cases of mass disasters. In catastrophic events, like mass disasters, wars, bomb blasts, large bones and joints are usually fragmented which lead to a difficulty in accurate age assessment of an individual. Ribs and other small bones, however, are found to be relatively intact in such events.

The sternal extremity of the rib has been studied widely in the developed world for accurately assessing the age of an individual from adolescence to the end-of-life span. It is expected that the rib would show age related metamorphosis observable by gross examination of the bone.<sup>2</sup>

**How to cite this article:** Bharti R, Saxena A. Age Estimation from Morphological Changes in Sternal End of Fifth Rib. J For Med Sci Law 2021;30(2):22-26.

**\*Corresponding author:** Dr. Anshul Saxena, Assistant Professor, Department of Forensic Medicine and Toxicology, School of Medical Sciences and Research, Sharda University, Greater Noida, UP, India. Pin-201306. Email- [anshul.saxena@gmail.com](mailto:anshul.saxena@gmail.com) (M) +91 8800648214.

Sternal ends of ribs are an accurate measure for age as they are being continuously used during life in breathing. Repeated use of chest wall in breathing, sternal extremities of ribs are maximally affected by age related changes. The sternal end of ribs shows the age-related metamorphosis throughout life and described under nine morphological phases based on a sample documented for age, sex and race.

## 2. Materials and Methods

This was a cross-sectional, descriptive study conducted at the Department of Forensic Medicine at tertiary care teaching medical institution. Hundred and fifty cases (75 male and 75 female), who were brought to the Department of Forensic Medicine for medico-legal autopsies and whose age was known and verified, were recruited. Informed consent was sought from the relatives of study participants before they were recruited. Ethical clearance was also sought from the Institutional Ethics Committee of this institution before the study was conducted. All cases aged between 10 and 70 years were included in the study. Cases having fractured, diseased or deformed fifth rib, those having any endocrinal or growth disorder, or those cases whose age was doubtful were excluded from the study.

The fifth rib from both sides was collected by the following method. The thorax was opened using routine autopsy technique. The sternal ends of fifth rib were removed after identifying and by cutting 2 inches (5cm) long portion along with the costochondral junction with the help of rib cutter. The cut portion was put in a boiling solution containing sodium bicarbonate and boiled for 20 minutes or until the soft tissue coverings have been removed. Following that, the rib was cleaned and dried at room temperature. The sternal ends of the ribs were examined with the help of magnifying lens and the mentioned morphological traits were noted (Various stages stated in [table no. 1 to 3](#))

- Component I (Pit depth)
- Component II (Pit Shape)
- Component III (Rim Shape and edges of rim wall).

The readings were recorded in a tabular form and were then assigned to six stages for each of the components. After recording the findings, the bones were placed back in the body. The collected data was entered in MS-Excel and analysed using MS-Excel and SPSS version 20. The data was summarized as means and proportions. One-way ANOVA was used to test for significance between the age of the study participant

and the stages of the morphological traits assessed by the observer.

**Table 1: Component I** – Pit depth (i.e., the maximum depth of the pit was measured with the depth caliper calibrated to 0.1mm).

Stage	Component findings
0	Flat to slight billowing with no indentation (pit) less than 1.1 mm.
A	Definite pit formation with a depth ranging from 1.1 to 2.5mm.
B	Pit depth ranging from 2.6 to 4.5mm.
C	Pit depth ranging from 4.6 to 7mm.
D	Pit depth ranging from 7.1 to 10mm.
E	Pit depth of 10.1mm or more.

**Table 2: Component II** – Pit shape. It was divided into six stages.

Stage	Component findings
0	Flat and billowy articular surface.
A	A shallow indentation.
B	Formation of V-shaped pit with thick walls.
C	The pit assumes a narrow U shape with fairly thick walls.
D	Wide U shape pit with thin walls.
E	Pit is still wide U shaped, yet deeper, more brittle and poorer in texture with some disintegration of bone.

**Table 3: Component III** – Shape of rim and edges of rim wall. It was divided into six stages.

Stage	Component findings
0	Smooth regular rim, with no wall formation.
A	Beginning walls with a thick, smooth regular rim.
B	Definite visible walls that is thick and smooth with a scalloped or slightly wavy rim.
C	The scalloped edges are disappearing wall are thinning yet the wall are fairly without fairly study without significant deterioration in the texture.
D	The rim is becoming sharper and increasingly irregular with more frequent bony Projection, often more pronounced at the cranial and caudal margins. The walls Shows further thinning cranial and are less sturdy with noticeable deterioration in texture.
E	Texture shows extreme friability and porosity, rim is very sharp, brittle and highly irregular with long bony projection. Occasionally windows are formed in areas where the walls are incomplete.

## 3. Results

When measuring pit depth for the right-sided rib, the mean age of the 27 cases showing Phase A changes was 22.11 ( $\pm 3.49$ ) years. Mean age of the 28 cases showing Phase B changes was 30.64 ( $\pm 10.69$ )

years. For the 35 cases showing Phase C changes, mean age was 37.40 ( $\pm 10.44$ ) years. Forty-one cases showing Phase D changes had mean age of 52.73 ( $\pm 8.91$ ) years, and Phase E changes showed by 19 cases had a mean age of 62.95 ( $\pm 10.96$ ) years.

For the left-sided rib, the mean age of 28 cases showing Phase A changes in Pit Depth was 22.64 ( $\pm 3.82$ ) years. Phase B changes were seen in 34 cases

with mean age of 30.38 ( $\pm 10.55$ ) years. Phase C consisted of 30 cases with mean age of 40.77 ( $\pm 11.74$ ) years. Phase D consisted of 42 cases with mean age of 53.17 ( $\pm 9.07$ ) years. Phase E changes were seen in 16 cases with mean age of 62.44 ( $\pm 11.70$ ) years.

Phase changes in pit depth, pit shape and rim shape (Fig. 1 to 3) were in accordance with the age of the individual, as presented in Table 4 to 6.

**Table 4: Analysis of Fifth Right & Left Rib according to Pit Depth (Stage A to E)**

Pit Depth	RIGHT			LEFT		
	N	Mean $\pm$ Std. Dev	Range	N	Mean $\pm$ Std. Dev	Range
A	27	22.11 $\pm$ 3.49	16-31	28	22.64 $\pm$ 3.82	16-33
B	28	30.64 $\pm$ 10.69	21-52	34	30.38 $\pm$ 10.55	20-52
C	35	37.40 $\pm$ 10.44	22-55	30	40.77 $\pm$ 11.74	25-62
D	41	52.73 $\pm$ 8.91	36-69	42	53.17 $\pm$ 9.07	35-73
E	19	62.95 $\pm$ 10.96	45-79	16	62.44 $\pm$ 11.70	45-79
Total	150	40.81 $\pm$ 16.45	16-79	150	40.81 $\pm$ 16.45	16-79

**Table 5: Analysis of Fifth Right & Left Rib according to Pit Shape (Stage A to E).**


Pit shape	RIGHT			LEFT		
	N	Mean $\pm$ Std. Dev	Range	N	Mean $\pm$ Std. Dev	Range
A	25	21.88 $\pm$ 3.39	16-31	27	21.67 $\pm$ 2.77	16-26
B	31	29.84 $\pm$ 9.61	21-52	30	31.67 $\pm$ 10.61	21-52
C	40	40.07 $\pm$ 12.02	22-62	39	39.67 $\pm$ 11.98	22-62
D	37	53.38 $\pm$ 8.63	42-72	35	54.49 $\pm$ 9.18	36-73
E	17	63.06 $\pm$ 11.15	45-79	19	59.63 $\pm$ 12.49	43-79
Total	150	40.81 $\pm$ 16.45	16-79	150	40.81 $\pm$ 16.45	16-79

**Table 6: Analysis of Fifth Right & Left Rib according to Rim Shape (Stage A to E).**

Rim Shape	RIGHT			LEFT		
	N	Mean $\pm$ Std. Dev	Range	N	Mean $\pm$ Std. Dev	Range
A	26	21.85 $\pm$ 3.07	16-28	25	21.60 $\pm$ 2.86	16-26
B	29	29.24 $\pm$ 8.87	21-51	29	29.69 $\pm$ 9.77	21-52
C	40	40.38 $\pm$ 11.92	22-62	41	40.15 $\pm$ 11.88	22-62
D	35	52.83 $\pm$ 9.06	36-73	34	52.56 $\pm$ 8.98	35-69
E	20	62.10 $\pm$ 10.77	45-79	21	61.33 $\pm$ 11.80	44-79
Total	150	40.81 $\pm$ 16.45	16-79	150	40.81 $\pm$ 16.45	16-79

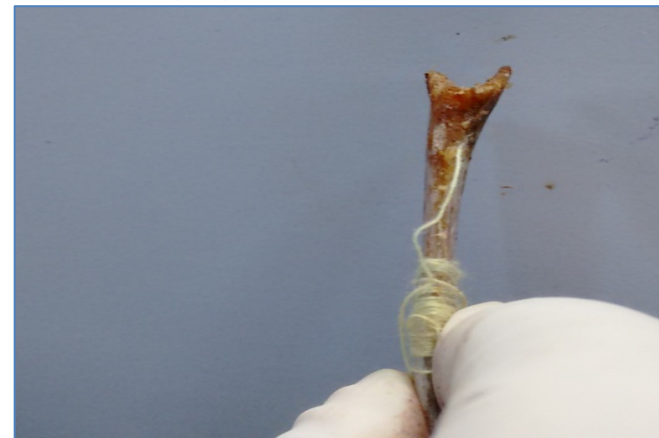Since there was a progressive increase in the mean age from Stage A to E of all morphological traits studied,

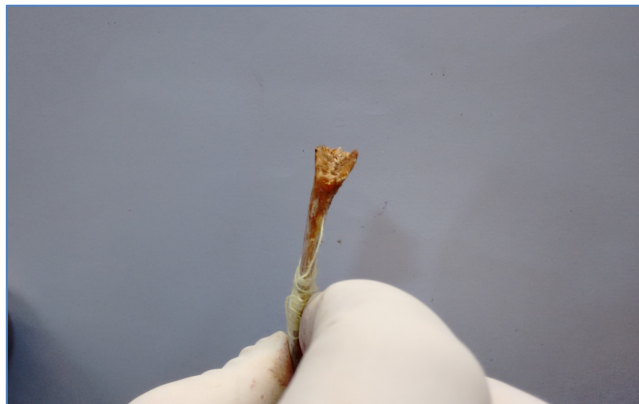**Figure 1: Wide u-shaped pit**



one-way ANOVA was used to test for significance between age and stage of individual morphological

**Figure 2: V-shaped pit**



**Figure 3: V-shaped pit with smooth walls**

traits. It was found that age was positively and significantly correlated with stage of all three morphological traits. Paired t-test failed to show any difference between right and left fifth rib for any variables analysed, indicating that there was comparison in the findings of both sides.

#### 4. Discussion

Osteological changes observed at the sternal rib ends are useful in adult age estimation. Currently most anthropologists employ the technique described by Iscan et al. The rates of these changes are in accordance to age and these changes are also different in females and males requiring the development of different standards.<sup>3</sup>

Several previous studies had reported the variation in morphological pattern of age associated changes in the sternal end of the ribs between various groups. In present study we discuss about the applicability of this component method to 5<sup>th</sup> rib of both sides. Mean age in all components for all the ribs was gradually increasing for score A through E in present study. The study results shown that the age of individual at death may be estimated from the rib within about 3 years in between third & fourth decade to about 6 years in the sixth decade and seventh decade of life. Pit depth and rim wall configuration combining shown better results than absolute pit shape alone. However total component score yielded better results than individual component alone.

One-way analysis of variance for fifth right rib indicated that 69.1% of studied ribs showed changes in pit depth, 66.9% of studied ribs showed changes in pit shape and 67.8% of studied ribs showed changes in rim shape and edges of rim wall, were in accordance with the age. On the left side, one-way analysis of variance of fifth rib indicated that, 66.5% of studied ribs showed changes in pit depth, 63.8% of studied ribs showed

changes in pit shape and 65.4% of studied ribs showed changes in rim shape and edges of rim, were in accordance with the age.

Phase changes in morphological traits estimated the age of the participants in our study with considerable accuracy. The analysis of variance statistic was found in total component score to be 73% in Iscan et al (1984)<sup>2</sup>, 79% in a study by Meena et al (2012)<sup>4</sup> and 83% was found in a study by Meena et al (2014)<sup>5</sup>. This was in comparable to our findings. No statistically significant variability was found in relation to the side of the ribs as paired T-test, failed to show any variations between right and left sides, with p-value being > 0.05. No statistically significant variability was detected in morphological changes in the sternal extremities of ribs from both ends. This finding is consistent with reports of Yogesh Tyagi et al<sup>6</sup>, Meena et al<sup>5</sup> and K. Padmakumar et al<sup>7</sup>.

The probable limitation of the study could be that we remain handicapped to predict the exact age from one single factor, as metamorphic changes in the sternal end of the fifth rib alone are not sufficient to assess the accurate age of a subject.

#### 5. Conclusion

Multifactorial parametric and comprehensive approach should be the hallmark for arriving to conclusion as regard to the age of the subject. It is essential, especially in medicolegal cases, to have demographic methods known to be accurate on adult Indian since few standards have been developed from Indian specimens.

The results of this study reveal that morphological changes in the sternal ends of the fourth ribs gave an encouraging result for estimation of age by component method also. Component method is useful to estimate the age in Indian throughout the adult life span. More studies with larger sample size are needed in India to further validate our findings.

**Conflict of interest:** None to declare.

**Ethical Clearance:** Yes.

**Source of funding:** Self.

#### References

1. Iscan MY, Loth SR, Wright RK. Age Estimation from the Rib by Phase Analysis: White Males. *J Forensic Sci.* 1984; 29(4): 100-4.
2. Iscan MY, Loth SR, Wright RK. Metamorphosis at the Sternal Rib End: A new method to estimate age at death in White Males. *American J Physical Anthropology.* 1984; 65(2): 147-56.

3. Aktas EO, Kocak A, Aktas S, Yemiscigil A. Ribs variation for age estimation. Are the standards for the right 4th rib applicable for other ribs? *Coll Antropol.* 2004;28 (2): 267–72.
4. Meena MC, Rani Y, Rani M. Bilateral metamorphological variation at sternal end of fourth rib. *Euras J Anthropol.* 2012; 3(2): 41–6.
5. Meena MC, Rani Y, Sharma GK. Age Estimation from the Rib by Components Method Analysis in Indian females. *Antrocom Online J of Anthropol.* 2014; 10(2): 143-9.
6. Tyagi, Y. & Kumar, A. & Kohli, Anil & Banerjee, K.K. Estimation of age by morphological study of sternal end of fourth ribs in females. *J Indian Forensic Sci.* 2009; 31(2): 87-94.
7. Padmakumar K, Girish S, Geetha O. Age estimation from the rib by phase analysis - An autopsy study in females. *J Punjab Acad Forensic Med Toxicol.* 2011; 11(2): 100-4.